

Select Language ▼

## Ruptured Cranial Cruciate Ligaments in Dogs

Wendy Brooks, DVM, DABVP

*Date Published: 04/11/2005*

*Date Reviewed/Revised: 08/16/2018*

### The Basics

The knee is a fairly complicated joint. It consists of the femur above, the tibia below, the kneecap (patella) in front, and the bean-like fabellae behind. Chunks of cartilage called the medial and lateral menisci fit between the femur and tibia like cushions. An assortment of ligaments holds everything together, allowing the knee to bend the way it should and keep it from bending the way it shouldn't.

There are two cruciate ligaments that cross inside the knee joint: the anterior (or, more correctly in animals, cranial) cruciate and the posterior (in animals, the caudal) cruciate. They connect from one side of the femur on top to the opposite side of the tibia on the bottom, the two ligaments forming an X (hence the name cruciate) inside the knee joint. They are named for their attachment site on the tibia (the cranial cruciate attaches to the front of the tibia and the caudal cruciate attaches to the back of the tibia). This may be hard to visualize based on the description but the illustration above shows the orientation of the two crossing ligaments effectively. The anterior/cranial cruciate ligament prevents the tibia from slipping forward out from under the femur.

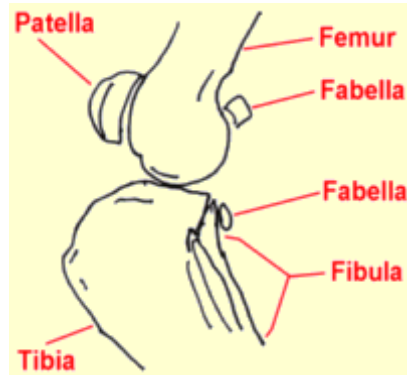


Illustration by MarVista Vet

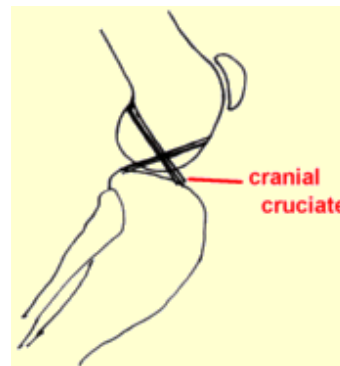
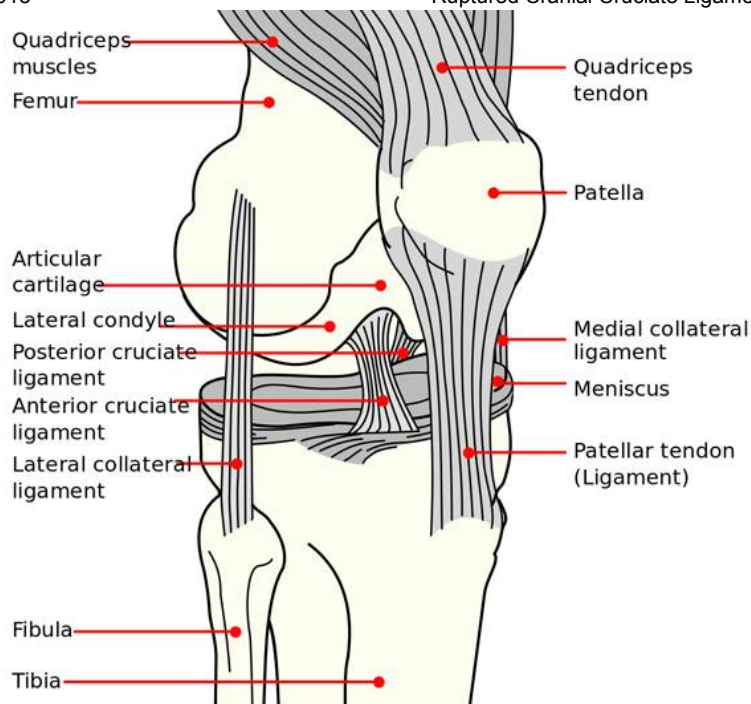


Illustration by  
MarVistaVet

### Finding the Rupture

The ruptured cruciate ligament is the most common knee injury of dogs; in fact, chances are that any dog with sudden rear leg lameness has a ruptured anterior cruciate ligament rather than something else. The history usually involves a rear leg suddenly so sore that the dog can hardly bear weight on it. If left



A forward view of the canine knee joint. Illustration is public domain via Wikipedia.

The veterinarian stabilizes the position of the femur with one hand and manipulates the tibia with the other hand. If the tibia moves forward (like a drawer being opened), the cruciate ligament is ruptured. (See a video of this manipulation.)

Another method is the tibial compression test where the veterinarian stabilizes the femur with one hand and flexes the ankle with the other hand. If the ligament is ruptured, again the tibia moves abnormally forward.

If the rupture occurred some time ago, there will be swelling on side of the knee joint that faces the other leg. This is called a medial buttress and is a sign that arthritis is well along.

It is not unusual for animals to be tense or frightened at the vet's office. Tense muscles can temporarily stabilize the knee, preventing demonstration of the drawer sign during examination. Often sedation is needed to get a good evaluation of the knee. This is especially true with larger dogs. Eliciting a drawer sign can be difficult if the ligament is only partially ruptured so a second opinion may be a good idea if the initial examination is inconclusive.

Since arthritis can set in relatively quickly after a cruciate ligament rupture, radiographs to assess arthritis are helpful. Another reason for radiographs is that occasionally when the cruciate ligament tears, a piece of bone where the ligament attaches to the tibia breaks off as well. This will require surgical repair and the surgeon will need to know about it before beginning surgery. Arthritis present prior to surgery limits the extent of the recovery after surgery though surgery is still needed to slow or even curtail further arthritis development.

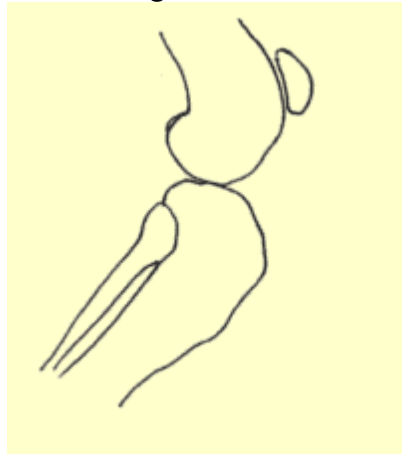
### How Rupture Happens

alone, it will appear to improve over the course of a week or two but the knee will be notably swollen and arthritis will set in quickly. Dogs are often seen by the veterinarian in either the acute stage shortly after the injury or in the chronic stage weeks or months later.

The key to the diagnosis of the ruptured cruciate ligament is the demonstration of an abnormal knee motion called a drawer sign. It is not possible for a normal knee to show this sign.

### The Drawer Sign

#### Drawer Sign



The drawer sign is exhibited when the tibia is able to forward from underneath the femur (similar to a drawer opening). If this action is demonstrated, the cruciate rupture is confirmed. The motion is exaggerated here for the purposes of illustration. Illustration by MarVistaVet.

Several clinical pictures are seen with ruptured cruciate ligaments. One is a young athletic dog playing roughly who takes a bad step and injures the knee. This is usually a sudden lameness in a young large-breed dog.

A recent study identified the following breeds as being particularly at risk for this phenomenon: Labrador retriever, Golden retriever, Rottweiler, Neapolitan mastiff, Newfoundland, Akita, St. Bernard, Rottweiler, Chesapeake Bay retriever, and American Staffordshire terrier.

On the other hand, an older large dog, especially if overweight, can have weakened ligaments and slowly stretch or partially tear them. The partial rupture may be detected or the problem may not become apparent until the ligament breaks completely. In this type of patient, stepping down off the bed or a small jump can be all it takes to break the ligament. The lameness may be acute but have features of more chronic joint disease or the lameness may simply be a more gradual/chronic problem.

**Larger, overweight dogs that rupture one cruciate ligament frequently rupture the other one within a year's time.**

**An owner should be prepared for another surgery in this time frame.**

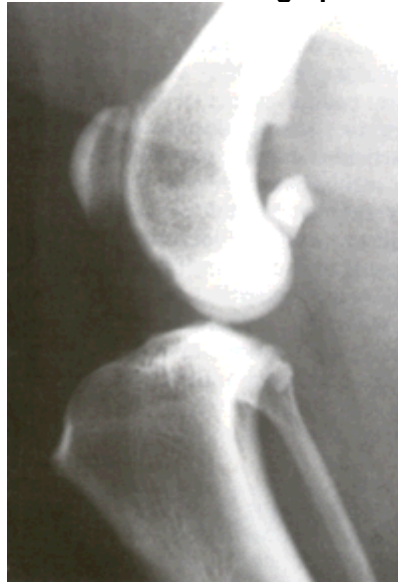The cranial cruciate rupture is not limited to large breed dogs. Small dogs can certainly rupture their ligaments as well and, while arthritis is slower to set in when the patient is not as heavy, there is an association with cruciate rupture and medial luxating patella that is very common in small breed dogs. With the patellar luxation, the kneecap flips in and out of the patellar groove. If the condition is relatively mild, it may not require surgical correction but it does stress the cranial cruciate ligament and can predispose to rupture and need to correct both conditions surgically.

### **What Happens if the Cruciate Rupture is Not Surgically Repaired**

Without an intact cruciate ligament, the knee is unstable. Wear between the bones and meniscal cartilage becomes abnormal and the joint begins to develop degenerative changes. Bone spurs called osteophytes develop resulting in chronic pain and loss of joint motion. This process can be arrested or slowed by surgery but cannot be reversed.

- Osteophytes are evident as soon as 1 to 3 weeks after the rupture in some patients. This kind of joint disease is substantially more difficult for a large breed dog to bear, though all dogs will ultimately show degenerative changes. Typically, after several weeks from the time of the acute injury, the dog may appear to get better but is not likely to become permanently normal.

**Normal Stifle Radiograph**



Courtesy MarVistaVet

**Radiograph Of A Damaged Stifle**

- In one study, a group of dogs was studied for 6 months after cruciate rupture. At the end of 6 months, 85% of dogs less than 30 pounds of body weight had regained near normal or improved function while only 19% of dogs over 30 pounds had regained near normal function. Both groups of dogs required at least 4 months to show maximum improvement.

### What Happens in Surgical Repair?

There are three different surgical repair techniques commonly used today. Every surgeon will have their own preference for which technique is best for a given patient's situation.

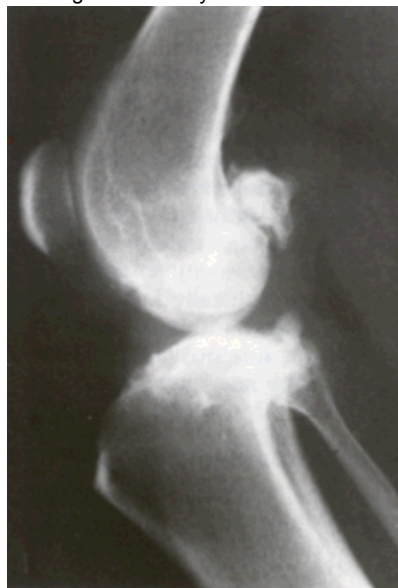#### *Extracapsular Repair*

This procedure represents the traditional surgical repair for the cruciate rupture. It can be performed without specialized equipment and is far less invasive than the newer procedures described below. First, the knee joint is opened and inspected. The torn or partly torn cruciate ligament is removed. Any bone spurs of significant size are bitten away with an instrument called a rongeur. If the meniscus is torn, the damaged portion is removed. A large, strong suture is passed around the fabella behind the knee and through a hole drilled in the front of the tibia. This tightens the joint to prevent the drawer motion, effectively taking over the job of the cruciate ligament.

- Typically, the dog may carry the leg up for a good two weeks after surgery but will increase knee use over the next 2 months eventually returning to normal.
- Typically, the dog will require 8 to 12 weeks of exercise restriction after surgery (no running, outside on a leash only including the backyard).
- The suture placed will break 2 to 12 months after surgery and the dog's own healed tissue will hold the knee.

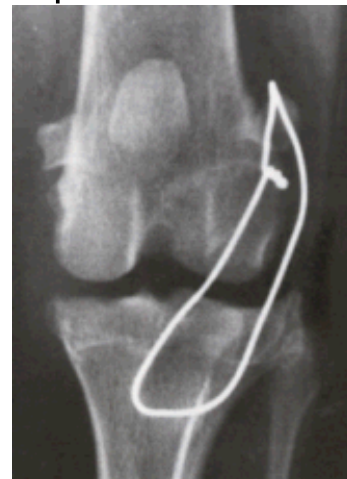#### *Tibial Plateau Leveling Osteotomy (TPLO)*

This procedure uses a fresh approach to the biomechanics of the knee joint and was developed with larger breed dogs in mind. The idea is to change the angle at which the femur bears weight on the flat "plateau" of the tibia. The tibia is cut and rotated in such a way that the natural weight-bearing of the dog actually stabilizes the knee joint. As before the knee joint still must be opened and damaged meniscus removed. The cruciate ligament remnants may or may not be removed depending on the degree of damage.



Courtesy MarVistaVet

#### Radiograph of a Repaired Stifle



Lateral placement of orthopedic wire. Radiograph by MarVistaVet.

This surgery is complex and involves special training in this specific technique. Many radiographs are necessary to calculate the angle of the osteotomy (the cut in the tibia). This procedure typically costs substantially more than the extracapsular repair as it is more invasive to the joint.

- Typically, most dogs are touching their toes to the ground by 10 days after surgery although it can take up to 3 weeks.
- As with other techniques, 8-12 weeks of exercise restriction are needed.
- Full function is generally achieved 3 to 4 months after surgery and the dog may return to normal activity.

### ***Tibial Tuberosity Advancement (TTA)***

The TTA similarly uses the biomechanics of the knee to create stability though this procedure changes the angle of the patellar ligament. This is done by cutting and repositioning the tibial crest where the patellar ligament attaches and implanting a titanium or steel "cage," "fork," and plate as well as bone grafts to stabilize the new angle. Like the TPLO, bone is cut, special equipment is needed including metal implant plates. Similar recoveries are seen relative to the TPLO.

### **Which Procedure is Better?**

The TTA and TPLO are much more invasive, much more expensive, and require special equipment and specially trained personnel. They have greater potential for complication. Are they worth it? For dogs under 45 lbs, it is generally accepted that there is no clear advantage of the newer procedures over extra capsular repair. For larger dogs, there is great controversy. For all the theory behind TPLO and TTA, results one year post-operative seem to be the same regardless of which of the three procedures the dog had performed. There is some evidence that recovery to normal function may be faster with the newer procedures. Controversy continues and there are strong opinions favoring each of the three procedures. Discuss options with your veterinarian in order to decide.

### **General Rehabilitation after Surgery**

Rehabilitation following the extracapsular repair method can begin as soon as the pet goes home. The area can be chilled with a padded ice pack for 10 minutes a couple times daily. (Do not try to make up for a skipped treatment by icing the area longer; prolonged cold exposure can cause injury.) Passive range of motion exercise where the knee is gently flexed and extended can also help. It is important not to induce pain when moving the limb. Let the patient guide you. Avoid twisting the leg. After the stitches or staples are out (or after the skin has healed in about 10 to 14 days), water treadmill exercise can be used if a facility is available. This requires strict observation and, if possible, the patient should wear a life jacket. Rehabilitation for patients with intracapsular repair is similar but slower in progression.

Rehabilitation after TPLO or TTA is gentler. Icing as above and rest are the main modes of therapy. After 3 to 4 weeks, an increase in light activity can be introduced. A water treadmill is helpful. No jumping, running or stair-climbing is allowed at first. Expect the osteotomy site to require a good 6 weeks to heal.

### **What if the Rupture Isn't Discovered for Years and Joint Disease is Already Advanced?**

A dog with arthritis pain from an old cruciate rupture may still benefit from a TPLO surgery and possibly from the TTA. Ask your veterinarian if it may be worth having a surgery specialist take a look at the knee. Most cases must make do with medical management. Visit our section on arthritis treatment.

### **Meniscal Injury**

We mentioned the menisci as part of the knee joint. The bones of all joints are capped with cartilage so as provide a slippery surface where the bones contact each other (if the bones contact each other without cartilage, they grind each other down). In addition to these cartilage caps, the stifle joint has two blocks of cartilage in-between the bones. These blocks are called the menisci and serve to distribute approximately 65% of the compressive load delivered to the knee. The only other joint with a meniscus is the jaw (temporo-mandibular joint).

When the crucial ligament ruptures, the medial (on the inner side of the knee) meniscus frequently tears and must either be removed, partly removed, or ideally repaired. This is generally done at the time of cruciate ligament surgery and we would be remiss not to mention it.

Pets with meniscal damage may have an audible clicking sound when they walk or when the knee is examined, but for a definitive diagnosis the menisci must actually be inspected during surgery. It is difficult to access the menisci and thus repairing a tear in the meniscus is problematic; furthermore, poor blood supply to the menisci also makes good healing less likely. For these reasons, removal of the damaged portion of the meniscus is the most common surgical choice. This leaves some meniscus behind to distribute the compression load on the knee but removes the painful, ineffective portion.

Areas of current research include techniques to improve blood supply to the healing meniscus so that repair can be more feasible. If meniscal damage has occurred in a cruciate rupture, arthritis is inevitable and surgery should be considered a palliative procedure.

### **Enhancing Recovery after Surgery**

#### ***Confinement***

Enhancing recovery post-operatively is largely about strict confinement early. This cannot be over-emphasized. Be prepared to crate your dog or employ a pen such as a child's playpen depending on the dog's size. A corral of sorts can be constructed with boxes and a baby gate. Be sure you understand the instructions with regard to gradual return to exercise over several months.

#### ***Adequan Injections***

A series of Adequan injections can help with joint inflammation as well as lubrication. Typically injections are given twice a week for a total of eight injections.

#### ***Glucosamine***

Oral joint supplements such as glucosamine contain cartilage building blocks to help the body repair cartilage damage. This is an excellent time to begin supplementation and there are numerous brands.

#### ***Weight Management***

Overweight dogs have an increased risk for arthritis and for cruciate rupture. A weight management program can reduce the potential for arthritis and can reduce the risk of rupture of the opposite cruciate ligament. If your dog is overweight, ask your vet about a weight management plan that might be started during the recovery period.

#### ***Professional Rehab/Physical Therapy***

Nothing compares to professional rehab for return to function. If you are lucky enough to have such a facility in your area, consider utilizing their services. A list of home exercises may be obtained and/or the dog can visit weekly or a few times weekly for exercise and treatment. Some facilities allow the dog to board and have daily treatment. Ask your vet about this option.

The content of this site is owned by Veterinary Information Network (VIN), and its reproduction and distribution may only be done with VIN's express permission.

The information contained here is for general purposes only and is not a substitute for advice from your veterinarian. Any reliance you place on such information is strictly at your own risk.

Links to non-VIN websites do not imply a recommendation or endorsement by VIN of the views or content contained within those sites.